

# Death Caused by Perioperative Fasting and Sedation in a Child with Unrecognized VLCAD

Charles R. Roe, MD, Hobart E. Wiltse, MD, PhD  
Lawrence Sweetman, PhD, and Linda L Alvarado, BS

## Abstract

An adopted 3 1/2-year-old girl with no prior medical problems died after a routine dental procedure. More than 2 years later, acylcarnitine analysis of dried blood found on her bedding revealed she had very long chain acyl-coenzyme A dehydrogenase (VLCAD) deficiency. Perioperative oral fasting, without intravenous administration of glucose, may be detrimental to children with certain metabolic and endocrine disorders. Newborn screening by tandem mass spectrometry will detect disorders of fatty acid oxidation such as VLCAD and allow early and preventive treatment. (J Pediatr 2000; 136:397-9)

Children who require even relatively minor operative procedures often require preoperative fasting, sedation, and anesthesia. For the most part, these practices have not been considered as significant risks. Ingebo et al (1) have examined the relationship of the fasting interval before endoscopy relative to the residual fluid contents in the stomach and found that only a 2-hour interval is necessary. This observation was very important, especially for children with underlying metabolic and endocrine disorders (2). Sedation before and after such procedures can result in further medication-imposed fasting. We report the death of a child with an unrecognized fat oxidation disorder, very long chain acyl-coenzyme A dehydrogenase deficiency, who required a restorative dental procedure.

## Case Report

A white female infant was born to a 21 -year-old woman (gravida 3) after a 42-week uneventful pregnancy. Her birth weight was 3.71 kg. She was relinquished to foster care and adopted at 6 months of age. At that time, she was considered developmentally normal although somewhat hypotonic. During her first 18 months, she experienced minor illnesses such as otitis media and 2 bouts of gastroenteritis without hospitalization. She also tolerated overnight fasting intervals of about 13 hours without morning symptoms of lethargy, confusion, combativeness, or excessive sweating.

At 3 years 8 months, she underwent a restorative dental procedure. For this procedure, her last light meal was at 4:00 AM. She received meperidine (pethidine), 35 mg, and chlorpromazine, 17.5 mg, by injection at 11: 00 AM, followed by nitrous oxide inhalation. She was sent home at noon still somnolent but arousable. She remained lethargic throughout the after noon and evening and consumed only small amounts of food and liquid. By 10:30 the next morning, she was unresponsive and exhibited repetitive stiffening and jerking movements (thought to be related to chlorpromazine) and was given diphenhydramine, 20 mg, in transit to the emergency department. On arrival, she had decorticate posturing and was unresponsive to painful stimuli. Ocular movements were dysconjugate with both pupils fixed and dilated. She died within 30 minutes of arrival. Initial laboratory findings revealed a blood glucose level of 6 mg/dL (0.33 mmol/L) and a blood urea nitrogen level of 35 mg/dL (12.5 mmol/L); aspartate aminotransferase and alanine aminotransferase levels were 118 and 76 IU/L, respectively. Urine ketones were detected, and a toxicology screen was negative.

CPT Carnitine palmitoyltransferase

MCAD Medium chain acyl-coenzyme A dehydrogenase

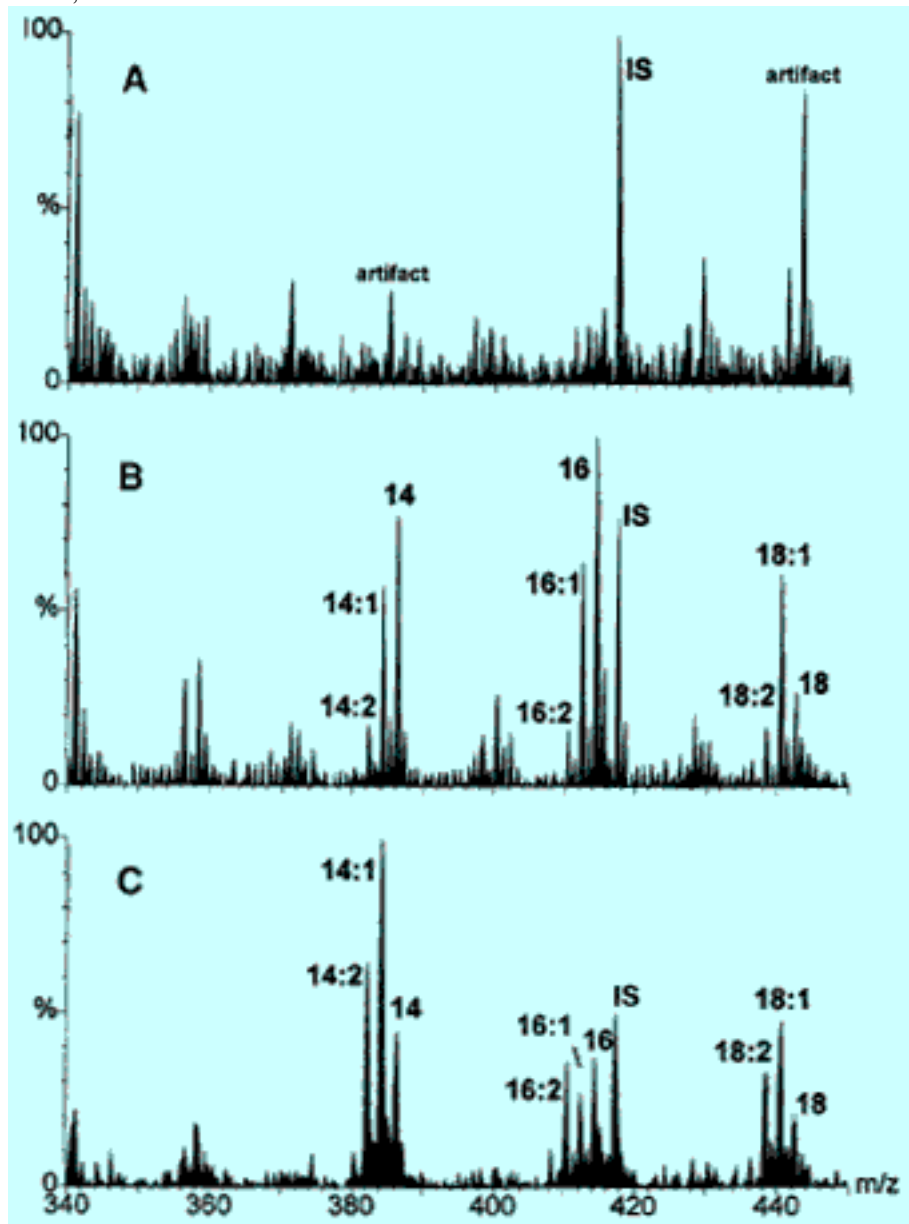
VLCAD Very long chain acyl-coenzyme A dehydrogenase

Postmortem examination revealed cerebral edema and marked vacuolization of liver cytoplasm suggestive of fatty infiltration with near absence of glycogen in liver, heart, kidney, and adrenal tissues. The A985G mutation, characteristic of medium chain acyl- coenzyme A dehydrogenase deficiency, was not detectable.

## Results

Two and a half years later, the adoptive family requested further assistance in determining the cause of death in this child. Frozen tissues or body fluids from the autopsy were not available. The only material available for analysis was the child's quilt, which had an area (~8 cm in diameter) saturated with dried blood from the dental extraction. A portion of this quilt, which contained areas with and without dried blood, was submitted for solvent extraction and acylcarnitine analysis. The profile of saturated and unsaturated acylcarnitine intermediates included the 14 and 16 carbon species that characterize VLCAD deficiency. This analysis simultaneously eliminates carnitine acylcarnitine translocase, carnitine palmitoyltransferase II, L-3-hydroxyacyl-coenzyme A dehydrogenase, and MCAD deficiencies (Figure).

**Figure.** Tandem mass spectrometry analysis for acylcarnitines (methyl esters). A, Solvent extract and analysis of quilt without blood. B, Analysis of portion of quilt saturated with blood from tooth extraction. C, Acylcarnitine profile from blood sample from a child with documented VLCAD deficiency. IS, Internal standard 2H6-Palmitoylcarnitine (m/z 420). Designations: 14 = myristoylcarnitine, 16 = palmitoylcarnitine, 14:1 = cis-5-myristenoylcarnitine (C14:1), 18:1 = oleoylcarnitine, etc.



## Discussion

This child's fate emphasizes the serious risks for apparently "normal" children with unrecognized mitochondrial fat oxidation disorders undergoing routine operative procedures. The combination of preoperative and post-operative fasting along with sedation produced an irreversible situation, which promoted lipolysis in this child with resultant profound hypoglycemia, coma, cerebral edema, and death. A recent review (3) of 30 children with VLCAD deficiency clearly demonstrates that there are 2 distinctly different phenotypes: a cardiomyopathic form and one with recurrent hypoglycemic episodes, clinically indistinguishable from MCAD or the late infantile form of CPT II deficiencies. At 3 years 8 months, this child most likely had the hypoglycemic phenotype of VLCAD deficiency. Unfortunately, there were no materials available for direct enzyme assay. Both forms are easily detected by blood acylcarnitine analysis, even in the neonatal period, before onset of symptoms. Successful treatments have been described for both phenotypes, including the cardiomyopathic form (4,5).

Preservation of physiologic fluids is essential for further postmortem diagnostic evaluation. A blood sample is often obtained for toxicology screening by medical examiners, and this sample can be useful for both acylcarnitine and molecular analyses. Saving blood on Guthrie screening cards, at the time of autopsy, can also be useful for the same analyses. Occasionally, the original newborn screening card may also be available. Cultured fibroblasts are rarely obtained unless there was a prior hospitalization in which a metabolic disease was suspected.

The actual incidences of mitochondrial fat oxidation disorders are not available except for MCAD deficiency (1:15,000-1 20,000 live births), which was determined by analysis for the common mutation, A985G, observed in 90% of cases occurring in white subjects of northern European origin. The actual frequencies or ethnic distributions of the other fat oxidation disorders have not been determined. Large-scale neonatal screening by tandem mass spectrometry will provide that information.

The patient in this report clearly had no prior history to even suggest the presence of VLCAD or any other inherited disorder. The necessity for prolonged fasting before operative procedures in children, to reduce the risk of aspiration, has recently been called into question (1, 2) and merits continuing evaluation. In children known to have fat oxidation disorders (eg, MCAD deficiency), intravenous administration of glucose (10%) is recommended before, during, and after the dental procedure, along with intravenous administration of L-carnitine, to avoid hypoglycemia caused by lipolysis (C. R. Roe, unpublished results).

The clinical severity of fat oxidation disorders, even in the same family, can be very unpredictable. Although a rare occurrence, asymptomatic affected siblings of patients with MCAD deficiency have been observed. Children affected with the other fat oxidation disorders (translocase, CPT I and CPT II, VLCAD, L-3-hydroxyacyl-coenzyme A dehydrogenase, trifunctional protein deficiency, and short chain acyl-coenzyme A dehydrogenase deficiency) are usually identified only when they become symptomatic. Most of these other disorders are also complicated because they can have several different clinical phenotypes (6). The nature of the symptoms often determines how easily they will be detected. Increasingly, cardiologists are seeking a metabolic explanation in the face of an infant with hypertrophic or dilated cardiomyopathy. Metabolic testing should also be considered as part of the workup for children with other symptoms of fat oxidation disorders (ie, unexplained hypoglycemia, seizures, hypotonia with developmental delay, myopathies, rhabdomyolysis, and episodes of lethargy and coma).

Treatment is now effective for many of these defects (MCAD, the infantile and adult forms of CPT II, mild translocase deficiency, carnitine uptake deficiency, both forms of VLCAD deficiency). Identification of an affected individual by screening can also lead to detection of pre-symptomatic siblings, as well as the opportunity for future prenatal detection.

**Neonatal screening by tandem mass spectrometry would be the most effective means of determining frequencies and ethnic distributions and early intervention to prevent the tragedy of sudden unexpected and frequently unexplained death in children affected by these inherited disorders (7).**

From the Kimberly H. Courtwright and Joseph W. Summers, Institute of Metabolic Disease, Baylor University Medical Center, Dallas, Texas, and the University of Nebraska Medical Center, Department of Pediatrics, Omaha, Nebraska.

Reprint requests: Charles R. Roe, MD, Institute of Metabolic Disease, Baylor University Medical Center, 3812 Elm St, Dallas, TX 75226.

**References**

1. Ingebo KR, Rayborn NJ, Hecht RM, Shelton MT, Silber GH, Shub MD. Sedation in children: adequacy of two- hour fasting. *J Pediatr* 1997; 131:155-8.
2. Gleghorn EE. Preoperative fasting: you don't have to be cruel to be kind [editorial]. *J Pediatr* 1997; 131:12-3.
3. Vianey-Saban C, Divry P, Roe CR, Nada MA, Brivet M, Zabot MT, et al. Mitochondrial very-long-chain acyl-coenzyme a dehydrogenase deficiency: clinical characteristics and diagnostic considerations in 30 patients. *Clin Chim Acta* 1998, 269:43-62.
4. Brown-Harrison MC, Nada MA, Sprecher H, Vianey-Saban C, Farquhar J, Gilladoga AC, et al. Very long chain acyl-CoA dehydrogenase deficiency: successful treatment of acute cardiomyopathy. *Biochem Mol Med* 1996;58:59-65.
5. Cox GF, Souri M, Aoyama T, Rockenmacher S, Varvogli L, Rohr F, et al. Reversal of severe hypertrophic cardiomyopathy and excellent neuropsychologic outcome in very-long-chain acyl-coenzyme A dehydrogenase deficiency. *J Pediatr* 1998;133: 247-53.
6. Roe CR, Coates PM. Acyl-CoA dehydrogenase deficiencies. In: Scriver CR, Beaudet AL, Sly WS, Valle D, editors. *The metabolic basis of inherited disease*. 7th ed. vol 1. New York: McGraw-Hill; 1995. p. 1501-33.
7. Levy HL. Neonatal screening by tandem mass spectrometry: a new era. *Clin Chem* 1998; 44:2401-2.

Submitted for publication Mar 31, 1999; revisions received July 8, 1999, and Oct 1, 1999; accepted Oct 13, 1999. Copyright © 2000 by Mosby, Inc. 0022-3476/2000/\$12.00 + 0 9/22/103853 doi: 10.10677/mpd.2000.103853

- **Reprint requests:** Charles R. Roe, MD, Institute of Metabolic Disease, Baylor University Medical Center, 3812 Elm St, Dallas, TX 75226
- [References](#)
- From the Kimberly H. Courtwright and Joseph W. Summers, Institute of Metabolic Disease, Baylor University Medical Center, Dallas, Texas, and the University of Nebraska Medical Center, Department of Pediatrics, Omaha, Nebraska